



13<sup>th</sup> International Symposium  
on Endovascular Therapeutics

# **Disaster Cases lower limb**

**Prof. Dr. Ulf Teichgräber**


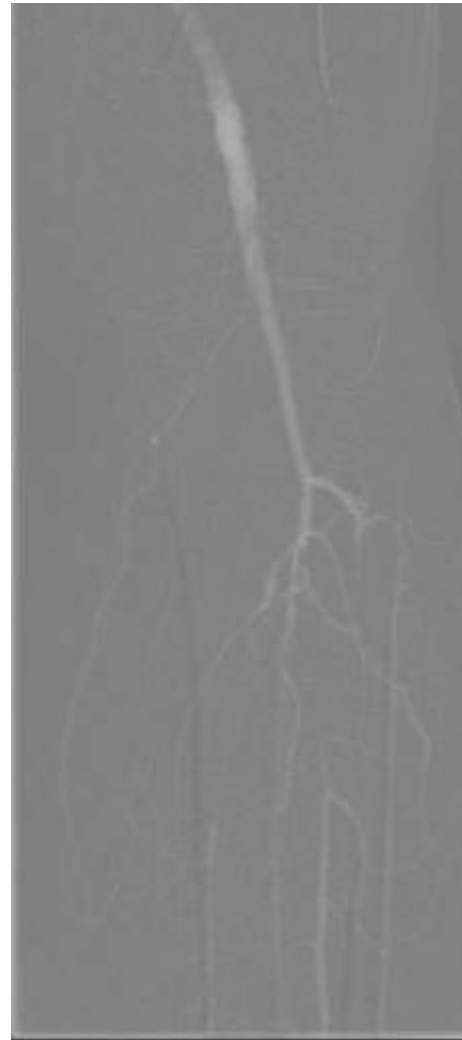
*Department of Radiology  
Universtiy Hospital Jena, Germany*

## Patient history

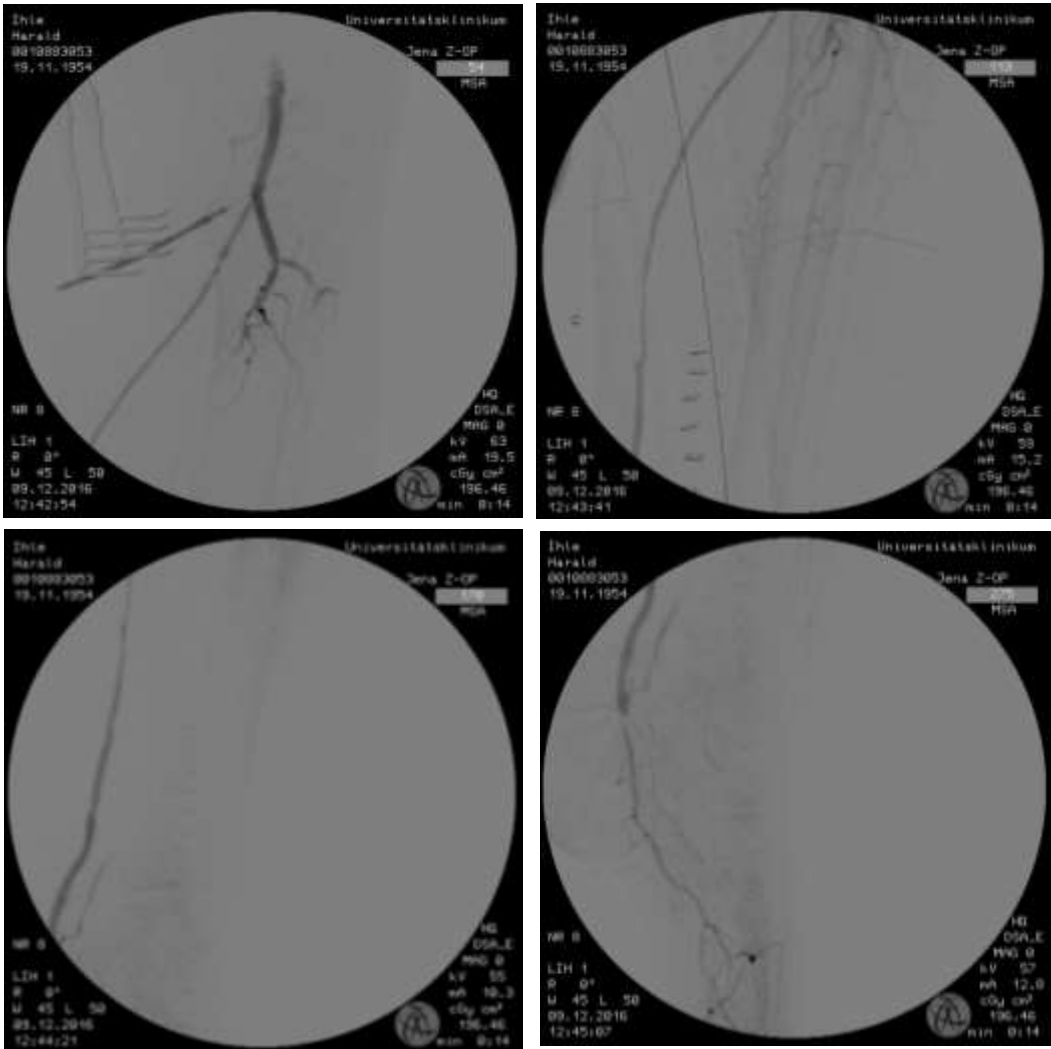
- 68 year old man
- Approx. 50 pack/years of smoking
- Diabetes
- CAD + PAD
- Rutherford V
- ABI left: 0.35 right: 0.65

## First Angiography 2016 (CO2):

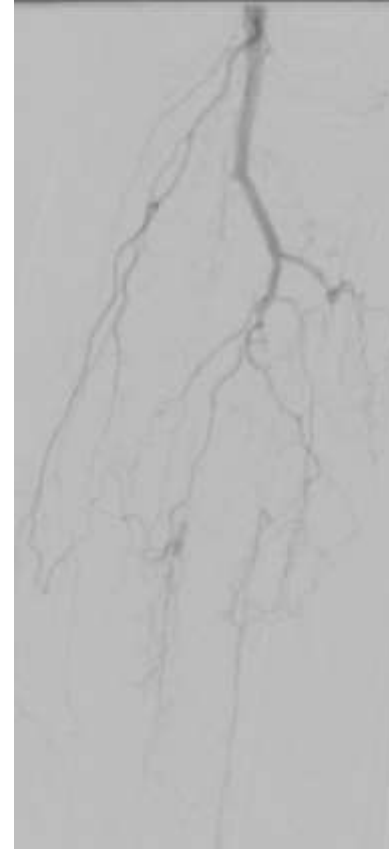
BTK left leg



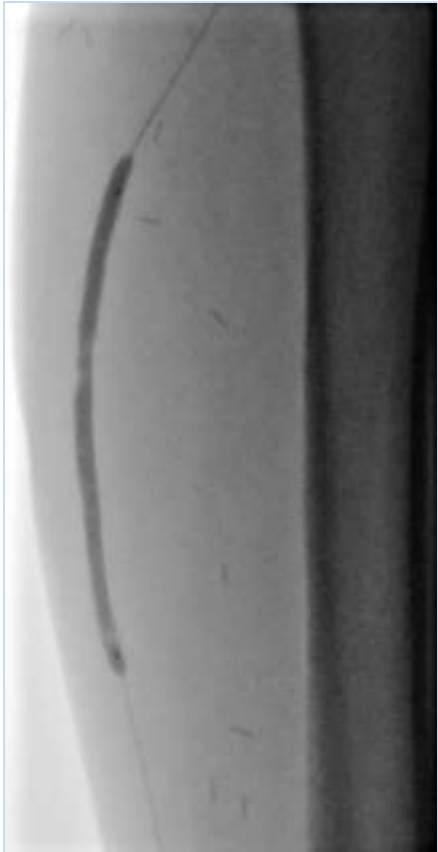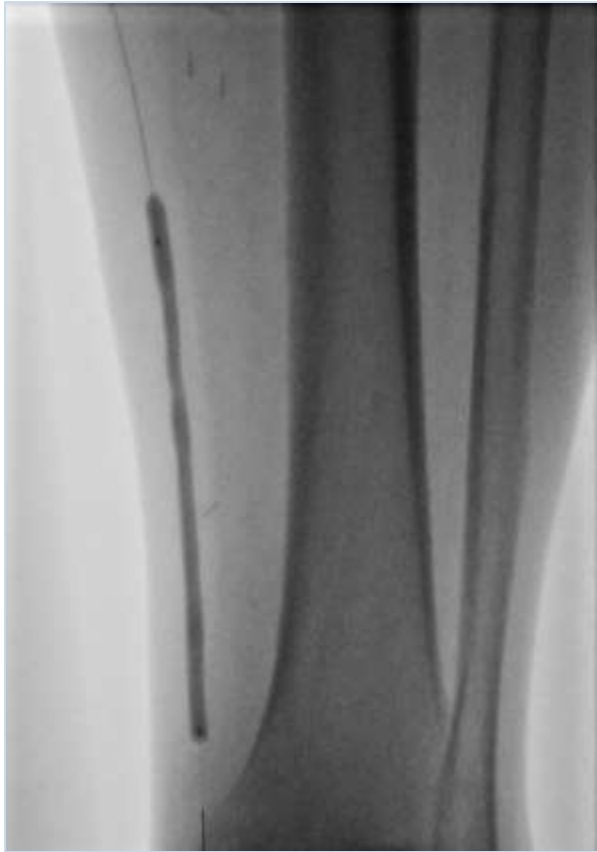# Infrapopliteal Bypass



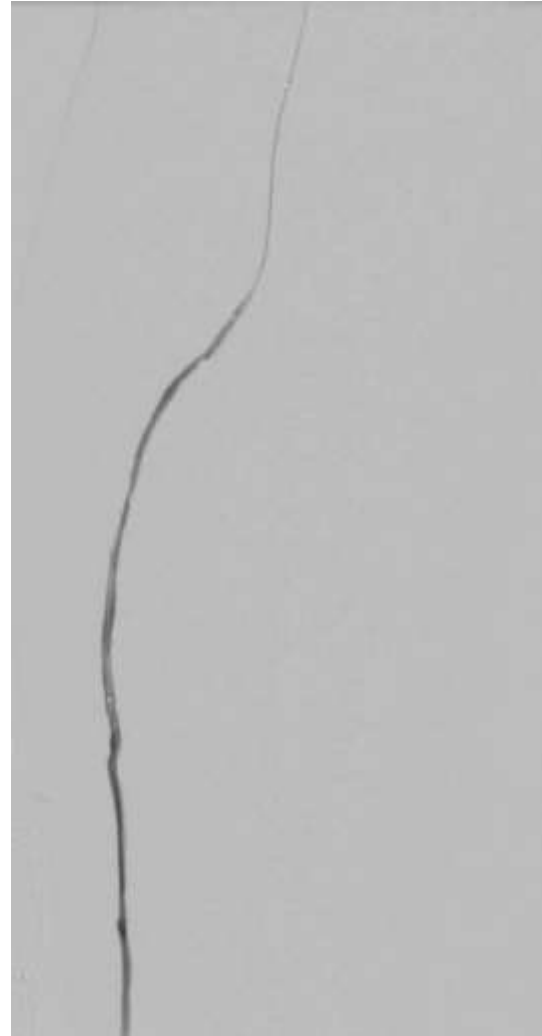
# Acute limb Ischemia (March 2019)



# Balloon angioplasty (March 2019)



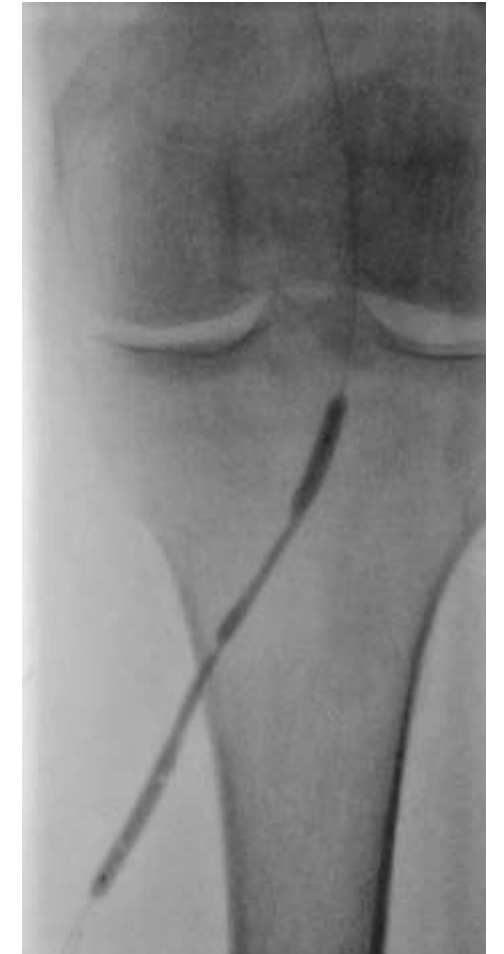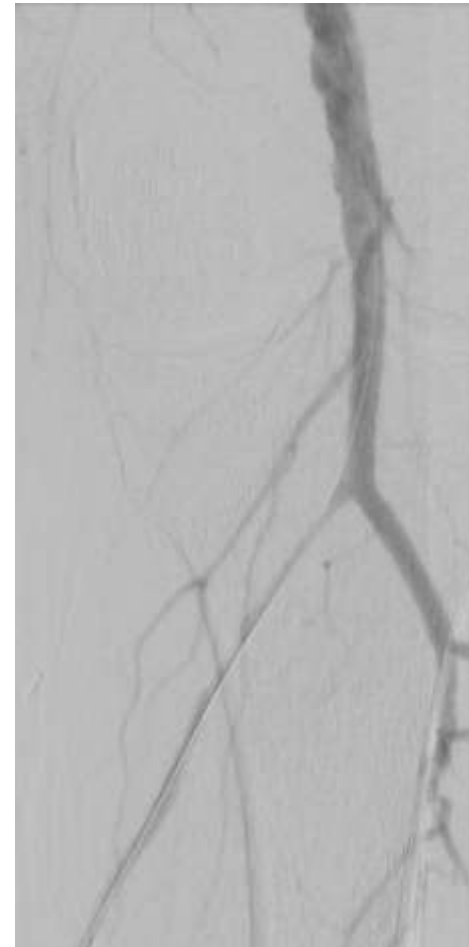
## Final result (March 2019)



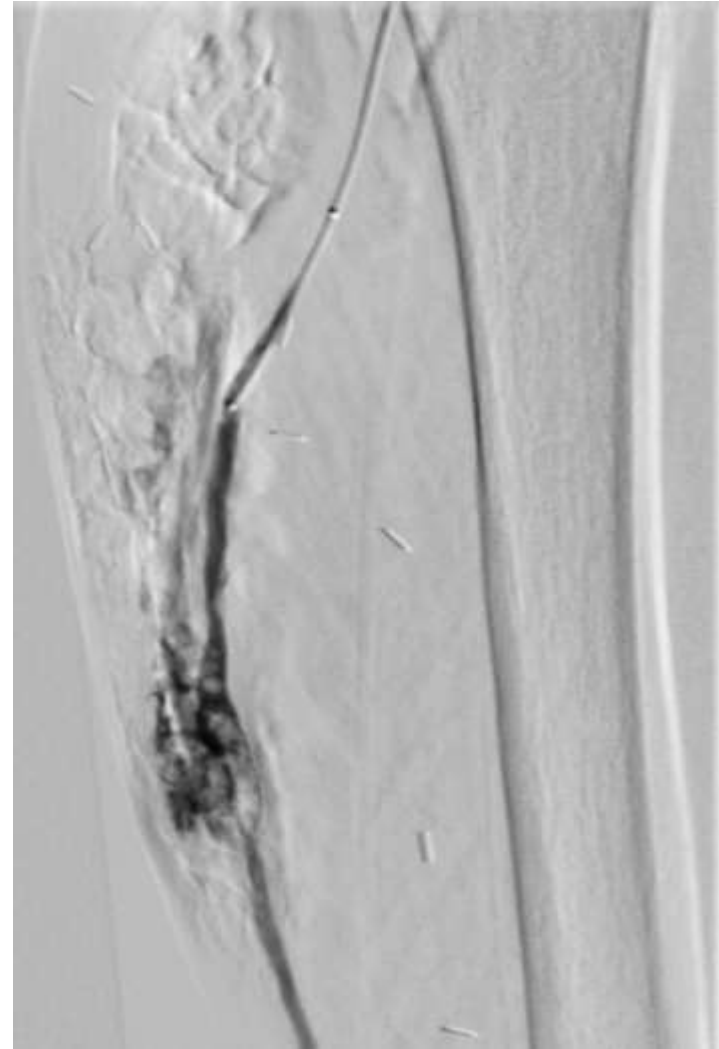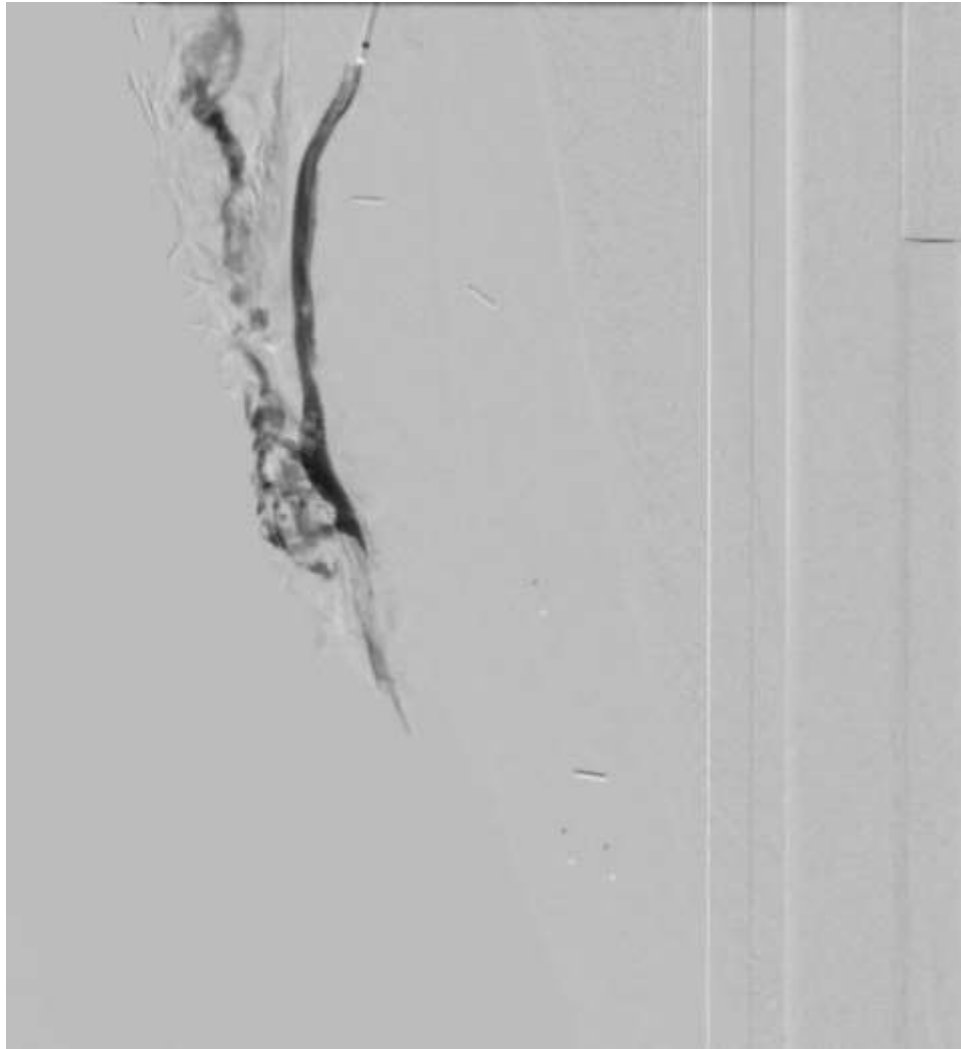
Followed by a overnight lysis therapy via i.a. infusion catheter (1.5 mg Actilysis/ hour)



## Follow-up next morning (March 2019)







## Take home messages:

- Lysis therapy after successful recanalization?
- The better is the enemy of the good
- Never remove your guidewire before the final run-off